

Acute kidney injury– an unusual complication of posaconazole use

Akan Otu, Felix Bongomin, Chris Kosmidis and David W. Denning

National Aspergillosis Centre, Wythenshawe Hospital, Manchester University NHS Foundation Trust, UK

Introduction

Posaconazole is an orally administered second-generation triazole antifungal agent which inhibits lanosterol 14-alpha-demethylase, an enzyme that converts lanosterol to ergosterol, a vital component of the fungal cell membrane.

Posaconazole has a favorable side effect profile, is safe and well tolerated when compared to the earlier generation of triazole antifungals.

Common side effects of posaconazole include gastrointestinal, hepatobiliary, neurological, and skin and subcutaneous disorders.

Renal disorders are classed as an uncommon side effect of posaconazole, occurring in ~0.1-1% of patients.

We report 2 episodes of acute kidney injury (AKI) attributed to posaconazole therapy in the same patient.

Case

A 74-year-old Caucasian male with chronic cavitary pulmonary aspergillosis (CCPA) complicating allergic bronchopulmonary aspergillosis (ABPA) was managed in the National Aspergillosis Centre, UK.

He had a past medical history of type II diabetes mellitus and adrenal insufficiency on steroid replacement.

He was previously treated with itraconazole for ABPA for 2 years but this was switched to voriconazole following the development of CCPA and loss of libido.

Voriconazole had to be switched to posaconazole (at a dose of 300mg once a day) after 5 weeks due to severe gastrointestinal adverse events and visual disturbances.

He took posaconazole for 5 years till his serum creatinine rose from 130 µmol/L to 158µmol/L with a reduction in his eGFR to 38mL/min, a urea of 13.6mmol/l, a potassium of 6.3mmol/L.

His alanine aminotransferase (ALT) was raised at 426IU/L and so was his alkaline phosphatase (380IU/L). His posaconazole levels were within the therapeutic range at 1.81mg/l.

Posaconazole was stopped.

His potassium fell to 5.9mmol/l over three days and he was discharged home.

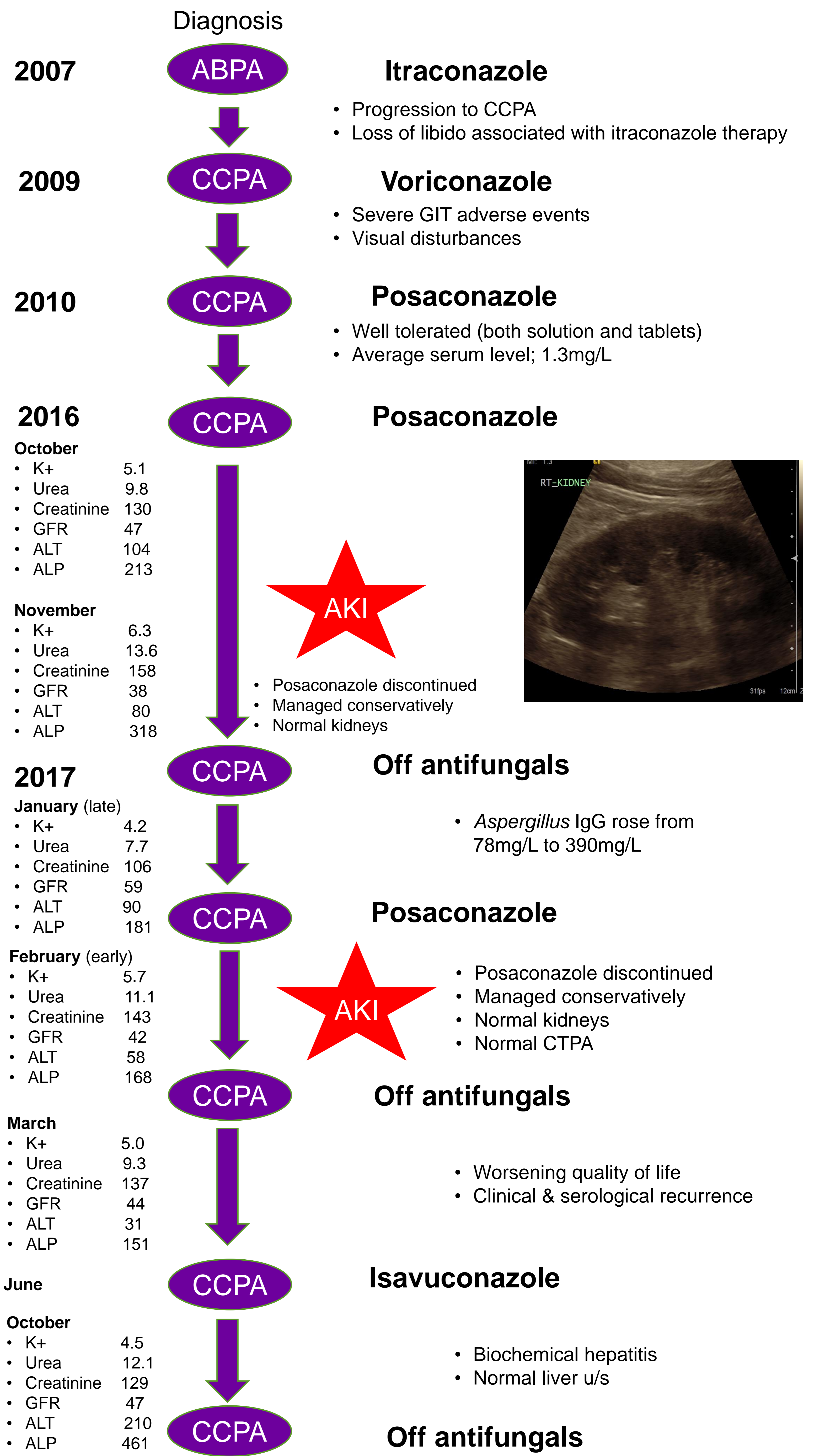
Four months later, his serum *Aspergillus*-specific IgG had increased from 78mg/L to 390mg/L and posaconazole tablets were recommenced (300mg once daily).

Two weeks later his serum urea rose to 11.1mmol/l with a raised creatinine of 143mmol/l, an eGFR of 42 mL/min and potassium of 5.7mmol/l with therapeutic posaconazole levels of 1.35mg/l.

Posaconazole was stopped, his serum creatinine and potassium normalized over a one week period.

Three months later, he was started on isavuconazole but this was discontinued after 5 months of treatment due to liver toxicity.

Case Summary



Conclusion

Posaconazole is predominantly metabolised and excreted through the liver; renal clearance is a minor elimination pathway. Mild-to-moderate renal impairment has no effect on the pharmacokinetics of posaconazole and thus no dose adjustment is recommended.

Though uncommon, AKI can result from posaconazole use. Regular monitoring of renal function is advocated for patients on posaconazole to facilitate early identification of AKI.